

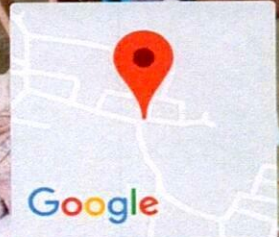
2-3-1-1
Photos

2.3.1

Community Based Medical Education



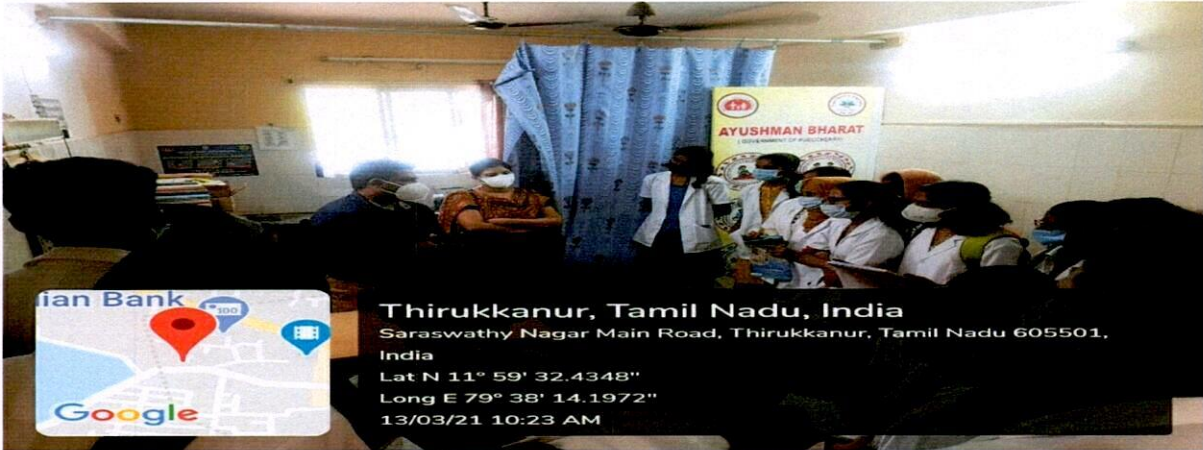Family Adoption Program



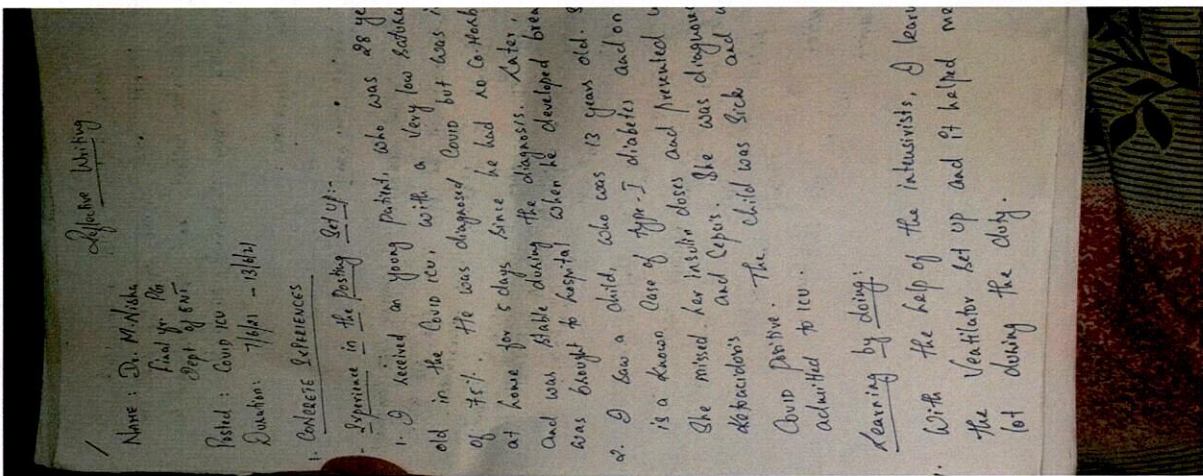
Thaduthatkondur, Tamil Nadu, India
R9QP+CC7, Thaduthatkondur, Tamil Nadu 607107, India
Lat 11.839077°
Long 79.38597°
24/01/23 12:41 PM

Dr. KAGNE. R.N
DEAN
SRI MANAKULA VINAYAGAR
MEDICAL COLLEGE & HOSPITAL
KALITHEERTHALKUPPAM,
PUDUCHERRY-605107.

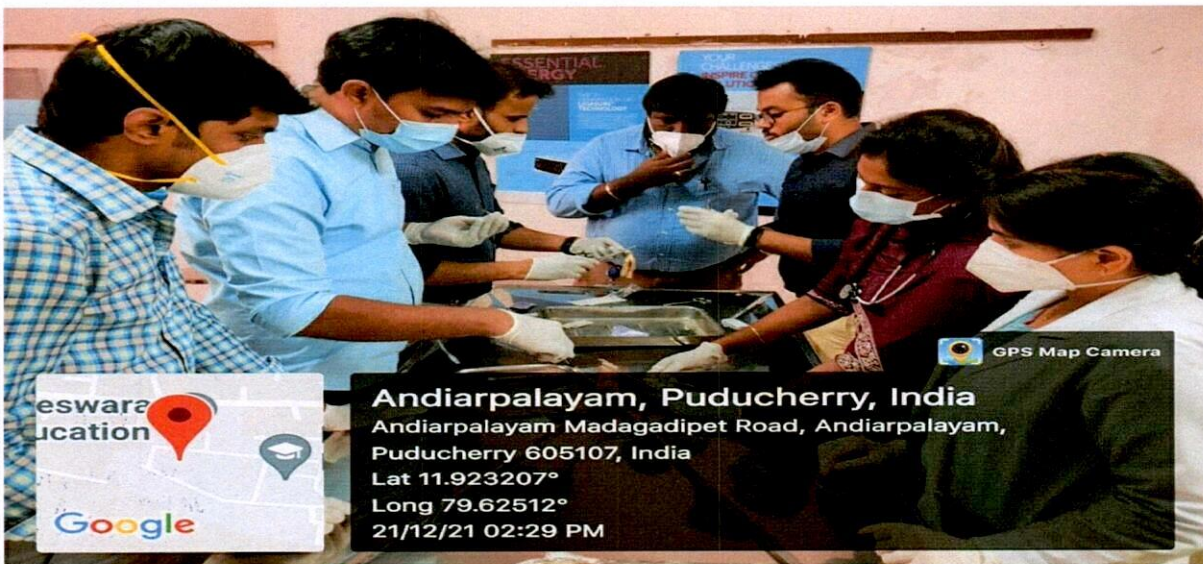
Field visits



Reflective Writing

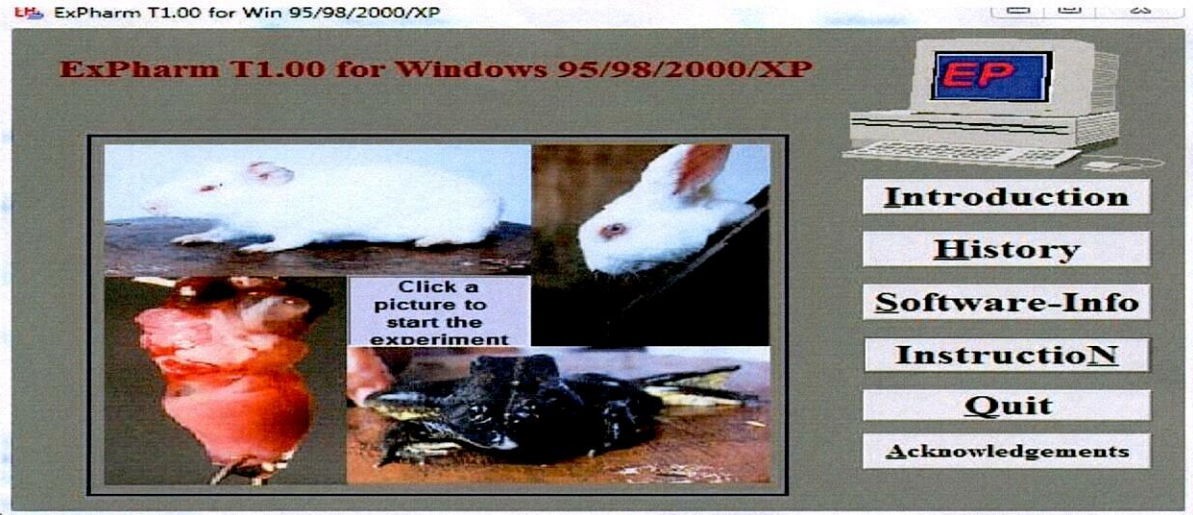

Skills Training

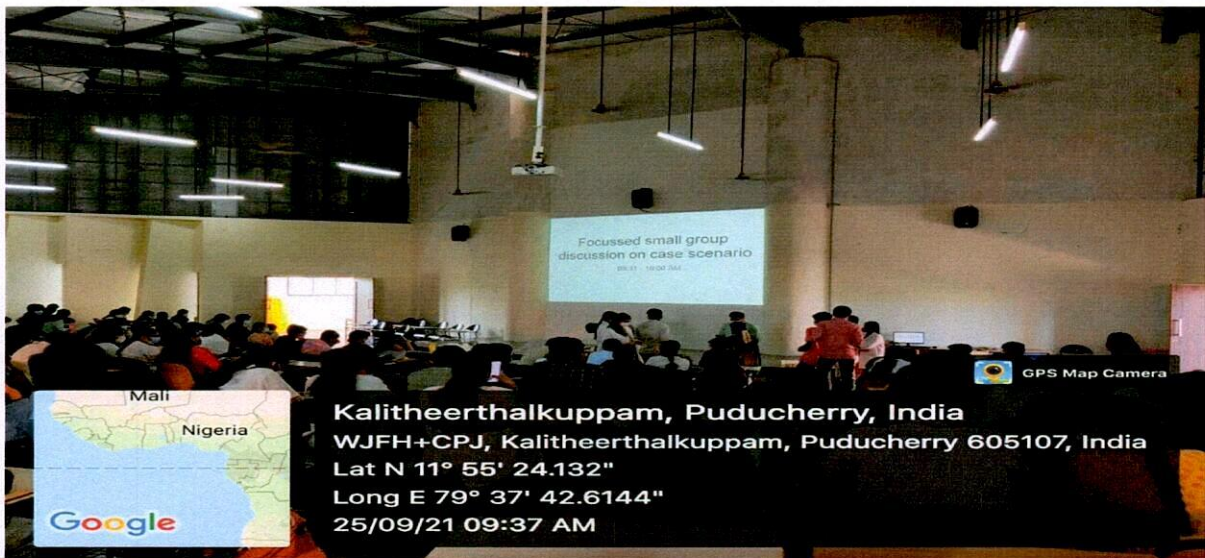


Dr. KAGNE. R.N
DEAN
SRI MANAKULA VINAYAGAR
MEDICAL COLLEGE & HOSPITAL
KALITHEERTHALKUPPAM,
PUDUCHERRY-605107.

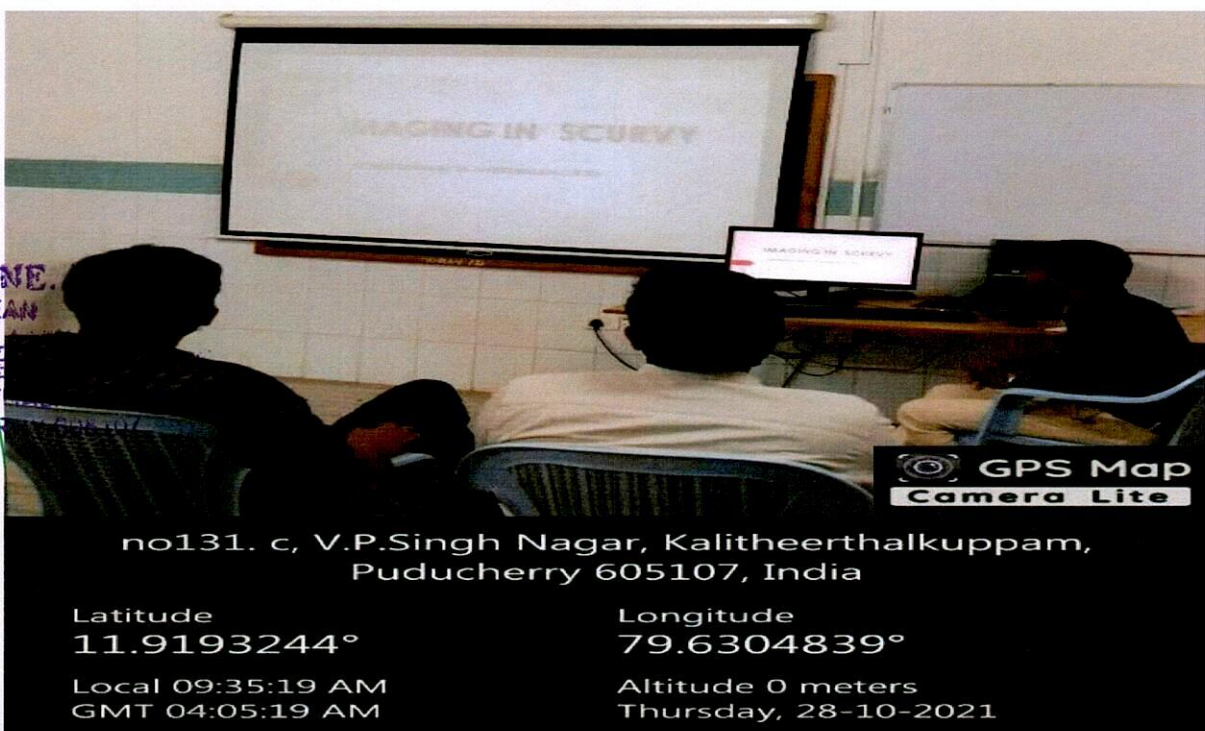
Computer Assisted Learning



Focused small group discussion



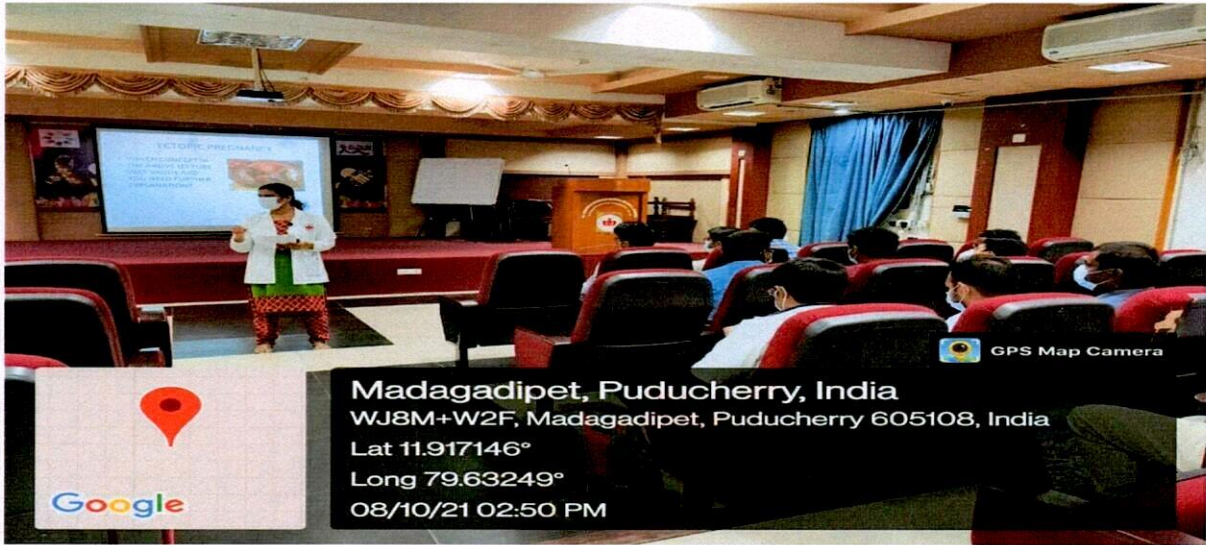
Group discussion



Dr. KAGNE,
DEAN

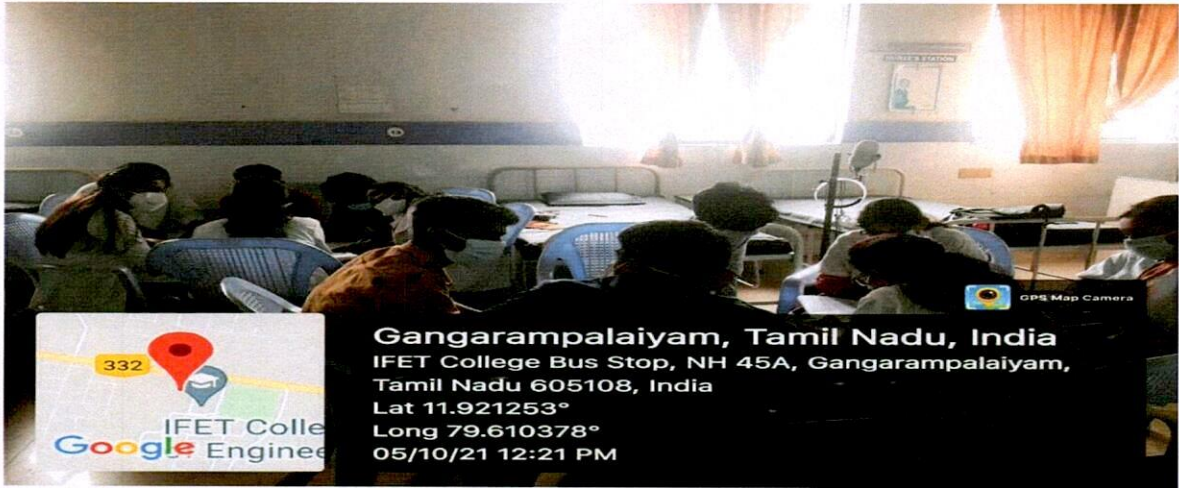
SRI MANAKUL
MEDICAL COLLEGE
KALITHEERT
PUDUCHERRY

Interactive Large group activities

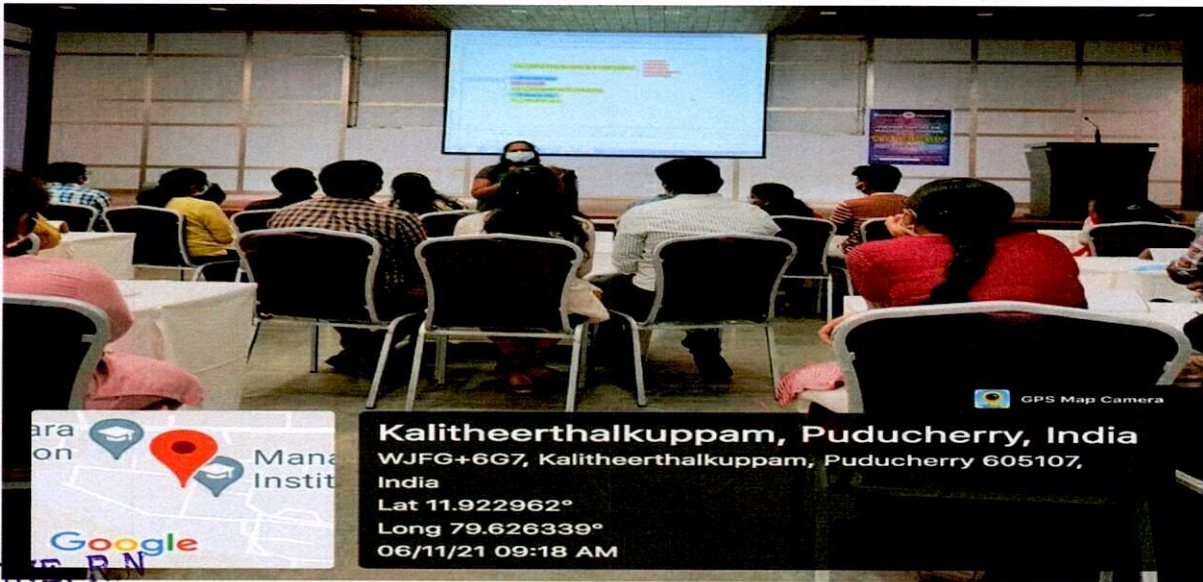

Interactive small group activities






UNCLE
MIND MAP

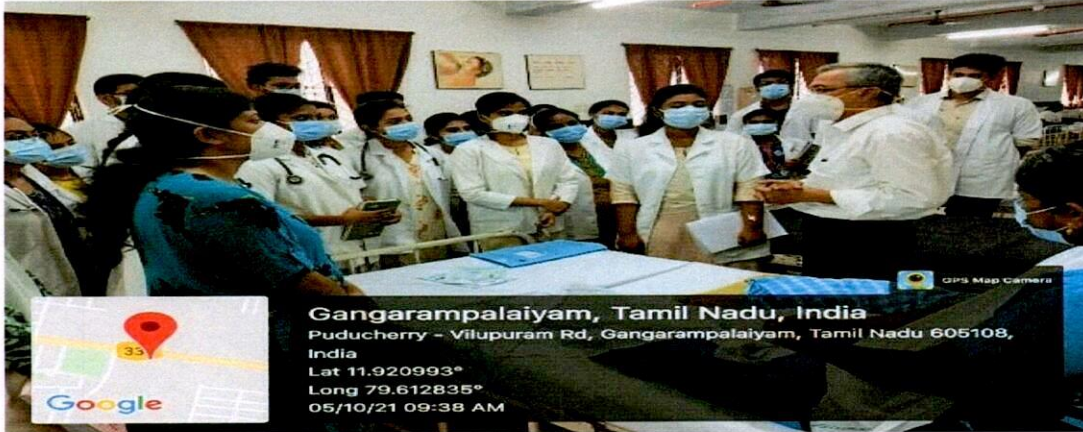

DR. KACHAR, R.N
 DEAN
 ANAKULA VINAYAGAR
 MEDICAL COLLEGE & HOSPITAL
 KALITHEERTHALKUPPAM,
 PUDUCHERRY-605107.

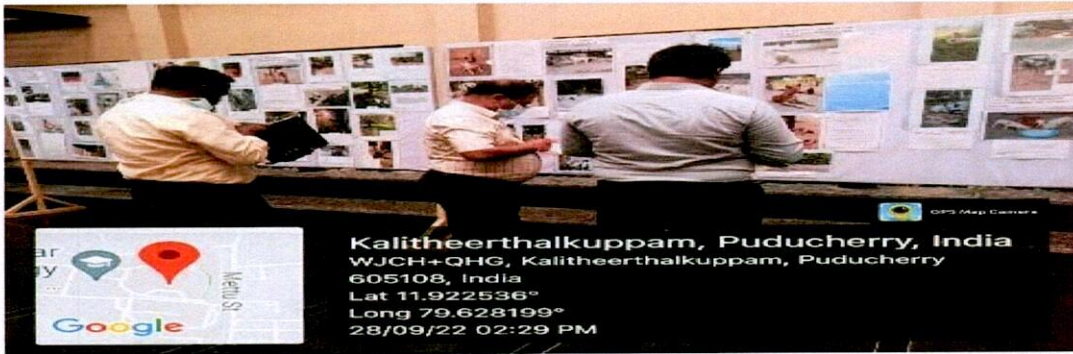SDL



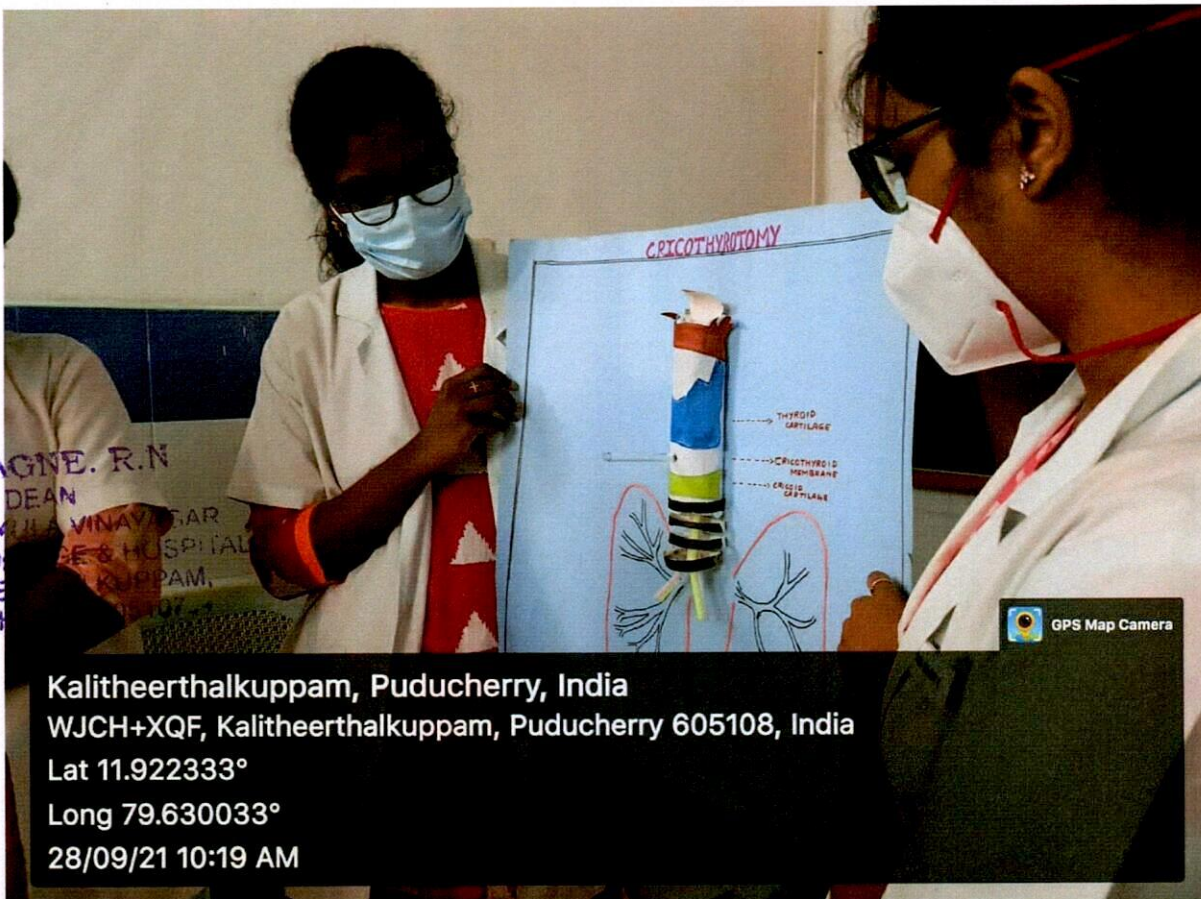
Patient centric and Evidence based learning




Learning from humanities



Project based

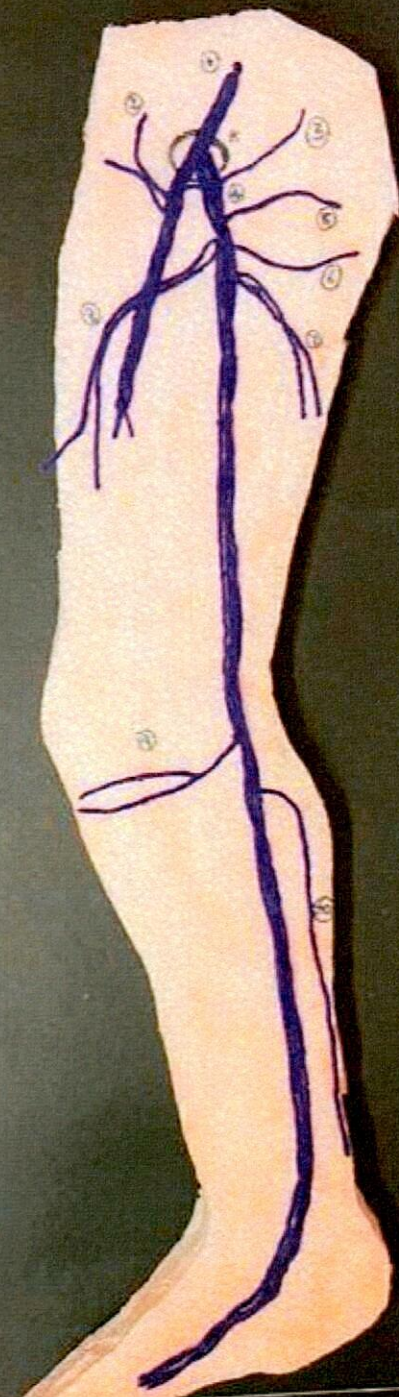




Dr. KAGNE, R.N.
DEAN
SRI MANAKULA VINAYAGAR
MEDICAL COLLEGE & HOSPITAL
KALITHEERTHALKUPPAM,
PUDUCHERRY-605107.

- N. JAYAPRABA &
K. VIJAYASURYA
(3rd year MBBS)

SAPHENOFEMORAL JUNCTION



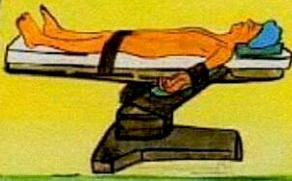
- SAPHENOFEMORAL JUNCTION AND ITS TRIBUTARIES
- * - SAPHENOFEMORAL JUNCTION
 - 1 - COMMON FEMORAL VEIN
 - 2 - SUPERFICIAL CIRCUMFLEX ILLIAC VEIN
 - 3 - SUPERFICIAL EPIGASTRIC VEIN
 - 4 - GREATER SAPHEMOUS VEIN
 - 5 - DEEP EXTERNAL PUDENDAL VEIN
 - 6 - SUPERFICIAL EXTERNAL PUDENDAL VEIN
 - 7 - POSTEROMEDIAL VEIN
 - 8 - ANTEROLATERAL VEIN
 - 9 - ANTERIOR TRIBUTARY VEIN
 - 10 - POSTERIOR ARCH VEIN

BY
KAMALIKA P.
LITTY MARIA AUGUSTINE
(EDS 0405)

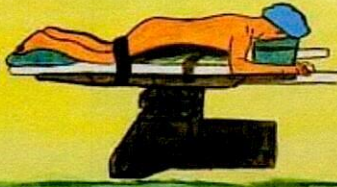
Dr. KAGNE. R.N
DEAN
SRI MANAKULA VINAYAGAR
MEDICAL COLLEGE & HOSPITAL
KALITHEERTHALKUPPAM,
PUDUCHERRY-605107.

DIFFERENT SURGICAL POSITIONS

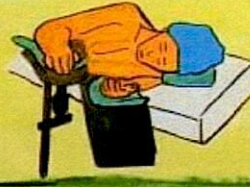SUPINE POSITION



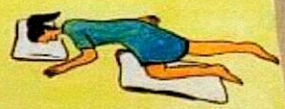PRONE POSITION



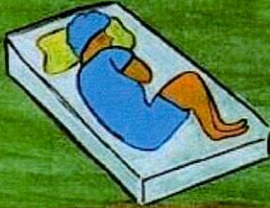LATERAL POSITION



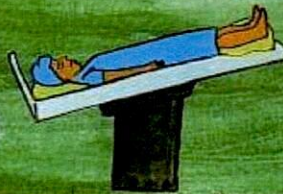
SIM'S POSITION




KNEE-CHEST POSITION



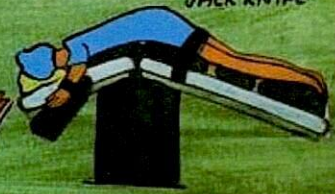
TRENDELENBURG'S



REVERSE TRENDELENBURG'S




KRASKE / JACK KNIFE




KIDNEY POSITION




LITHOTOMY POSITION



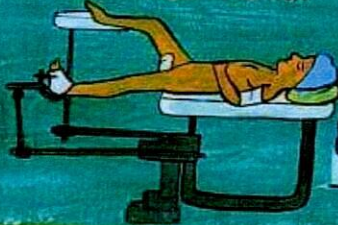FOWLER'S POSITION



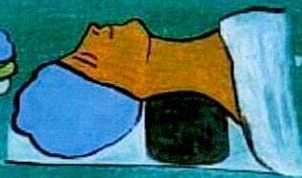SEMI-FOWLER'S POSITION



FRACTURE-TABLE POSITION



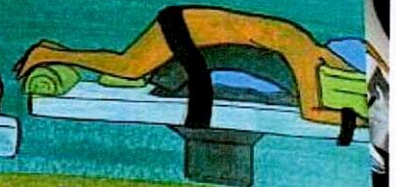ROSE'S POSITION



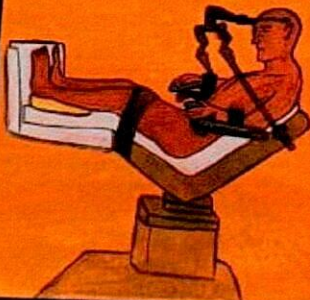ORTHOPNEIC POSITION



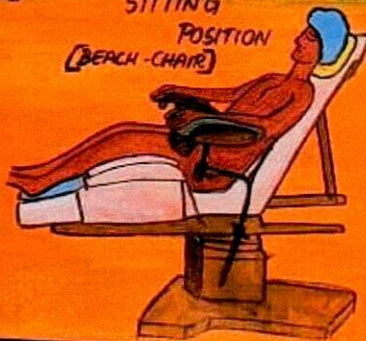
PRONE POSITION



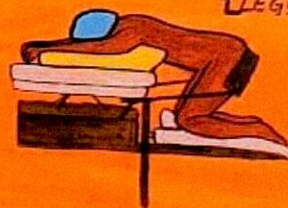SITTING WITH MAYFIELD HEAD PIN



SITTING POSITION (BEACH-CHAIR)



KNEE-CHEST POSITION [LEGS BENT AT KNEE AT 90°]



- N. JAYAPRABA &
K. VIJAYASURNA
IIIrd year MBBS

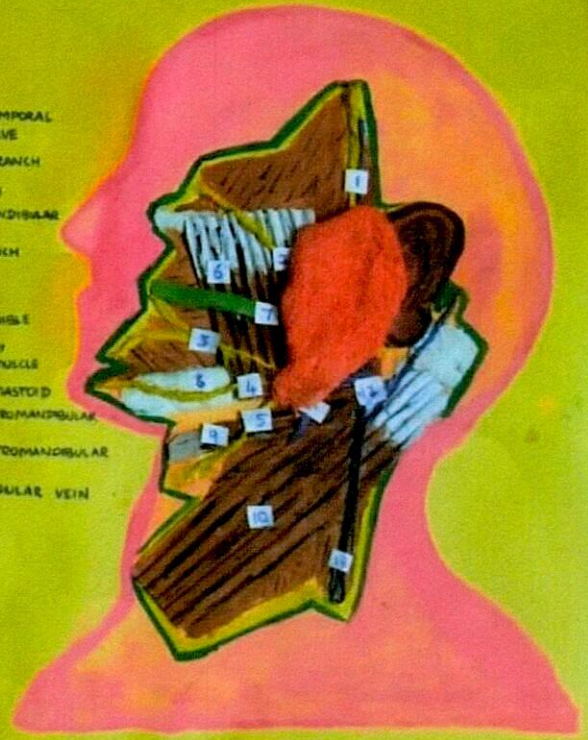Dr. KAGNE, R.N
DEAN
SRI MANAKULA VINAYAGAR
MEDICAL COLLEGE & HOSPITAL
KALITHEERTHAKUPPAM,
PUDUCHERRY-605107.

SUPERFICIAL PAROTIDECTOMY

MODIFIED BLAIR/
SISTRUNK APPROACH
[LAZY 'S' INCISION]



1. SUPERFICIAL TEMPORAL VESSEL & NERVE
2. ZYGOMATIC BRANCH
3. BUCCAL BRANCH
4. MARGINAL MANDIBULAR BRANCH
5. CERVICAL BRANCH
6. MASSETER
7. PAROTID DUCT
8. BODY OF MANDIBLE
9. POSTERIOR BELLY OF DIGASTRIC MUSCLE
10. STERNOCLAVICOMASTOID
11. ANTERIOR RETROMANDIBULAR VEIN
12. POSTERIOR RETROMANDIBULAR VEIN
13. EXTERNAL JUGULAR VEIN




Dr. KAGNE. R.N
DEAN
SRI MANAKULA VINAYAGAR
MEDICAL COLLEGE & HOSPITAL
KALITHEERTHALKUPPAM,
PUDUCHERRY-605107.

AXILLARY DISSECTION


DONE BY: SRINITHI RUPASHRI

- 1 PECTORALIS MINOR
- 2 PECTORALIS MAJOR
- 3 AXILLARY NERVE
- 4 AXILLARY VEIN
- 5 AXILLARY ARTERY
- 6 INTERCOSTOBRACHIAL NERVE
- 7 THORACODORSAL BUNDLE
- 8 LATERAL THORACIC VEIN AND ARTERY
- 9 LONG THORACIC NERVE
- 10 MEDIAL PECTORAL NERVE



Dr. KAGNE. R.N
DEAN
SRI MANAKULA VINAYAGAR
MEDICAL COLLEGE & HOSPITAL
KALITHEERTHALKUPPAM,
PUDUCHERRY-605107.

CANCER AWARENESS



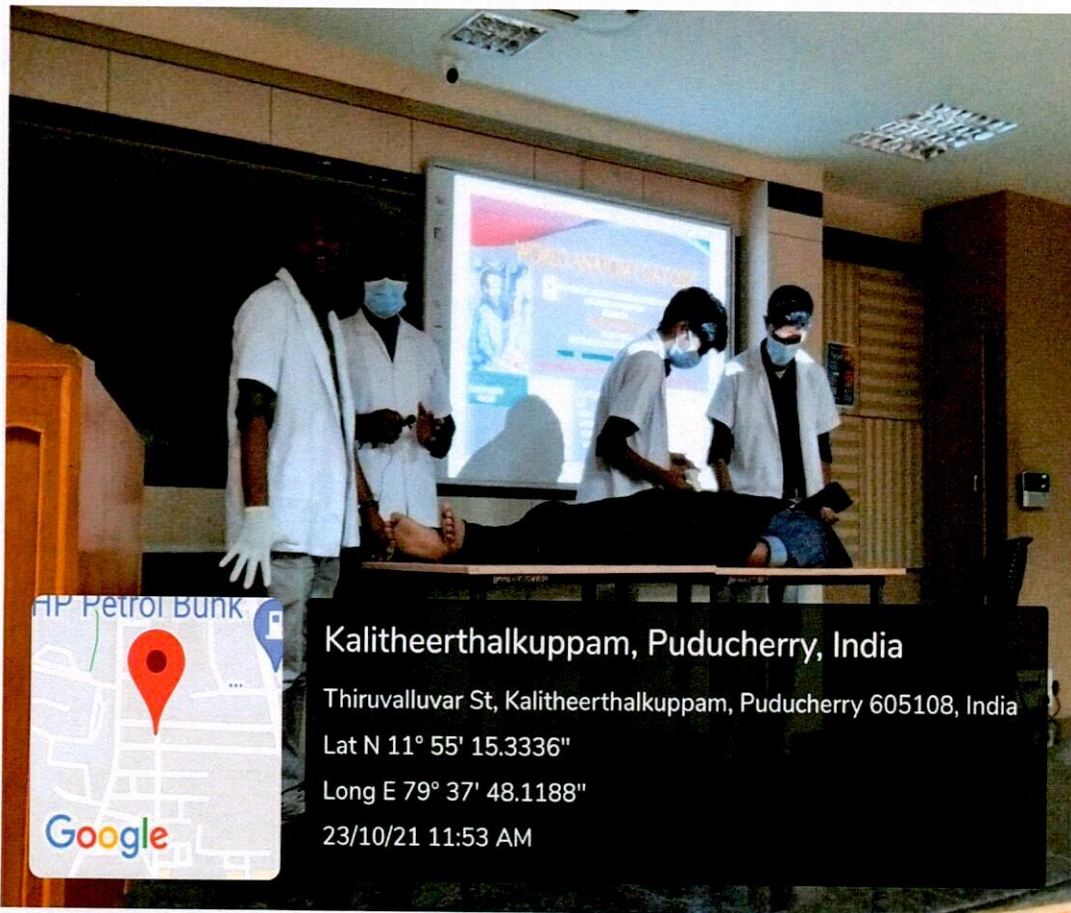

D. ARVIND
S. NITHYASHREE 2nd yr MBBS


Dr. KAGNE. R.N
DEAN
SRI MANAKULA VINAYAGAR
MEDICAL COLLEGE & HOSPITAL
KALITHEERTHALKUPPAM,
PUDUCHERRY-605107.




Dr. KAGNE. R.N
DEAN
SRI MANAKULA VINAYAGAR
MEDICAL COLLEGE & HOSPITAL
KALITHEERTHALKUPPAM,
PUDUCHERRY-605107

ROLEPLAY




Dr. KAGNE. R.N
DEAN
SRI MANAKULA VINAYAGAR
MEDICAL COLLEGE & HOSPITAL
KALITHEERTHALKUPPAM,
PUDUCHERRY-605107.